



## New Horizons Journal of Basic and Applied Sciences

# The role of scorpion, *Leiurus quinquestriatus*, and bee, *Apis mellifera* crude venoms in controlling schistosomal activity of Swiss Albino mice

Ismail Atia<sup>1,\*</sup>, Mohsen A Moustafa<sup>1</sup>, Omar S.O. Amer<sup>1</sup>, Alaa MH El-Bitar<sup>1</sup> and Naser Abdelsater<sup>1</sup>

<sup>1</sup> Zoology Department, Faculty of Science, Al-Azhar University, Assuit 71524, Egypt

Received: 11, 04, 2025; Accepted: 21, 07, 2025; Published: 21, 08, 2025

© 2026 The Author(s). Published by Science Park Publisher. This is an open access article under the CC BY 4.0 license (<https://creativecommons.org/licenses/by/4.0/>)

### Abstract

The harmful effects of schistosomiasis come primarily from the presence of adult stages and egg deposition in the blood vessels and tissues of the host which activates immunologic granulomatous reaction causing liver injury and fibrosis. Studies revealed promising results of natural extracted venoms against schistosomiasis. We aimed to evaluate the ability of scorpion *Leiurus quinquestriatus* (SV) and bee, *Apis mellifera* (BV) venoms to diminish worm load, reduce liver injury and initiate recovery following *S. mansoni* injury. Sixty Swiss albino mice were divided into two groups: a negative control group (n=10), and a second group exposed to  $65 \pm 5$  *S. mansoni* cercariae via subcutaneous injection (n=50). Then classified into 5 subgroups (10 mice each); one was left as a positive control, and the other four subgroups were respectively administered with (SV 0.1 mg/kg/week, SV then BV 0.1 mg each/kg/week, SV and BV 0.1 mg each/ kg/week mixed dose, and SV then BV 0.2 mg each/kg/week respectively), two doses for two weeks. After the 9<sup>th</sup> week, mice were sacrificed; liver, and kidney functions, histopathological examinations, and worm parameters were assessed. The treated groups showed significant enhancements in the liver and kidney functions, supported by the liver histopathological sections. Worm burden was reduced with increased dead ova count, reflected in the granuloma disorganized formation. The administration of scorpion and bee venom has a considerable role against *S. mansoni* infection and activity; moreover, it also has capability to can restore the liver functionality after liver injury.

**Keywords:** Anti-schistosomiasis, crude venom, granuloma, tegmental spines, liver functionality

## 1. Introduction

Despite animal venoms being previously thought to be lethal, the naturally extracted venoms have attracted considerable attention as a source of hope in the treatment of numerous epidemic and neglected diseases, for which chemical compounds show negligence in their treatment [1]. Naturally extracted venoms are widely used to obtain many pharmaceutical compounds for developing different therapies [2].

Schistosomiasis is one of the worldwide health problems affecting humans as well as domestic and wild animals [3]. Over 779 million people are at risk of infection in Latin America,

Africa, and Asia [4]. Intestinal schistosomiasis caused by *S. mansoni* lives in the lumens of the intestine, the worm activity and lays eggs in the endothelial lining of the venous capillary walls of the small portal venules, causing the formation of granulomas and periportal liver fibrosis [5].

The process of egg deposition in tissues activates an immunologic reaction, reflected in the granulomatous response that results in collagenases and fibrosis, including T cells, macrophages, eosinophils, and initial inflammatory reaction [6]. Praziquantel's effect becomes limited, also harmful side effects besides the loss of activity with long use, attracted attention to develop new treatment strategies [7, 8].

## Research Article

Scorpion, *Leiurus quinquestriatus* venom is composed of different components, including mucopolysaccharides, hyaluronidase, phospholipase, peptides, and enzymes [9]. The effectiveness of scorpion venom peptides with anti-parasitic activity, demonstrated to be an interesting tool for the treatment against parasites, was proved in-vitro in many parasite infections like Leishmania, Malaria, and Trypanosoma [10, 11].

Bee, *Apis mellifera* venom contains many active components including, melittin, apamin, mast cell degranulating peptide, adolapin, phospholipase A2, hyaluronidase, and amino acids [12].

Bee venom phospholipase A2 particle binding shows anti-plasmodium activity by inhibiting malaria parasite development in transgenic mosquitoes, also indicating that lipolyzed particles or lipid products are responsible for parasite killing [13]. Melittin was also found to have an effective role in killing *Trypanosoma cruzi* parasites [14].

Besides this, bee venom has healing activity, anti-inflammatory, antioxidant, immunity-boosting effects [15] and inhibition of inflammation mediators, which have a role in accelerating the wound healing process [16, 17]. This suggests that bee venom may be a potential treatment for liver inflammation, decreasing fibrosis and Pathogenic cytokine storm.

We aimed to use a combination of scorpion, *Leiurus quinquestriatus*, and bee, *Apis mellifera* venoms against schistosomal infection, which may produce new compounds that may have a synergetic role as they improve killing functionality, induce healing ability, and restore functionality to diminish the parasite effects in Schistosoma-infected mice.

## 2. Materials and Methods

### 2.1. Animals

Sixty adult male Swiss albino mice (CD-1 strain) weighing 25-30 g were purchased from Theodor Bilharz Research Institute (TBRI) in Giza, Egypt, and brought to the Parasitology Lab at the Zoology Department, Faculty of Science, Al-Azhar University (Assiut branch). The experiment on animals was conducted based on the guidelines and approval of the faculty Research Ethics Committee (No.AZHAR3/2024).

#### 2.1.1. Mice infection

Mice were categorized into six groups. Each group consisted of (n=10). One of them was left as a negative control group, and the other five groups were infected with 65±5 *S.*

*mansoni* cercariae subcutaneously for each mouse. These cercariae were purchased from Theodor Bilharz Research Institute (TBRI) in Giza, Egypt. The infected mice were kept for 49 days (7 weeks) incubation period, followed by two weeks of treatment, and the sacrifice was in day 62 (9<sup>th</sup> week).

### 2.2. Preparation of venoms and determination of LD<sub>50</sub>

Scorpion, *Leiurus quinquestriatus*, and Bee, *Apis mellifera* venoms, were extracted from living scorpions and bees using the electrical stimulation method of venom (ESV) [12, 18]. The venom was lyophilized and kept at -20°C.

The lethal potency dose of scorpion, *Leiurus quinquestriatus* venom, was determined [19]. Five mice were allocated for each group per dose of venom, serial venom concentrations started with 0.1, 0.2, 0.3, and 0.4 mg/kg, which were injected via the subcutaneous route of administration. Bee, *Apis mellifera* venom lethal potency dose was determined previously as 0.1 mg/kg [20].

### 2.3. Experimental design

After the incubation period of parasite (7 weeks), animals were allocated to six groups, ten mice each (A: negative control, B: positive control, C, D, E, and F: treated groups), all groups except negative and positive control groups received two treatment doses of scorpion and/or bee venoms subcutaneously one per week as follow: Negative and positive control groups received distilled water (DW) (100µl /week), while the other four groups (C, D, E, and F) received SV (0.1 mg/kg/week), SV then BV (0.1 mg each/kg/week), SV and BV (0.1 mg each/kg/week) mixed dose, and SV then BV (0.2 mg each/kg/week) respectively. By the end of the experiment, all animals were sacrificed, and then samples were collected for further investigation and measurements.

#### 2.3.1. Body weight changes

The body weight of all animal groups was calculated at the beginning and the end of this study using the following equation: Body weight gain (%) = [(final body weight – initial body weight) / initial body weight] \* 100. (1)

#### 2.3.2. Determination of serum biochemistry

At the end of the experiment, 2 mL of blood was drawn in serum separation tubes from the retroorbital sinus of infected and treated mice. The serum biochemical factors including liver function factors (Albumin and Aminotransferases; ASAT and ALAT), renal function factors (creatinine and urea), and some

## Research Article

elements (calcium  $\text{Ca}^+$  and Phosphorus  $\text{Ph}^+$ ) All the remaining chemicals and diagnostic kits were procured from Bio diagnostic Co., (Giza, Egypt) and Sigma Chemical Company, St. Louis, USA. were assessed using Spectrophotometric method by Mindray BA-800M Chemistry Analyzer (Thermo Fisher Scientific-Massachusetts-United States).

### 2.3.3. Worm load count

Hepatic portal and mesenteric vessels were perfused according to the method of [21] to recover worms. The recovered worms from each animal group were sexed and counted for single and copulated worms.

### 2.3.4. Tissue egg counts

At the end of perfusion, the whole small intestine was removed and three fragments of it (1 cm length) and the liver were cut, then washed with 5% potassium hydroxide (KOH) solution, and each was put on a glass slide to assess the number of eggs [22].

### 2.3.5. The oogram pattern

0.5 g of liver and intestine tissues was taken from each mouse and placed in a falcon tube containing 5 mL of 5 % potassium hydroxide (KOH) solution and incubated at 37°C for 24 h until the tissue was completely hydrolyzed. 0.1mL of the digested tissue was piped out from each tube and placed on a counting slide. The number of ova per gram of liver or intestinal tissue was counted for the immature, mature, and dead ova [23].

### 2.3.6. Liver granuloma assessment

Small pieces of liver from different groups were collected and preserved in 10% buffer-neutral formalin saline. 5  $\mu\text{m}$  thick sections of the tissues in paraffin were microtomed and processed using hematoxylin and eosin stain technique, then investigated by light microscope to determine the granuloma size, condensations, and deformations [24].

### 2.3.7. Screening of the worm's tegument surface

#### Scanning Electron Microscope (SEM)

The worms were fixed for 4 hours in 2% M sodium cacodylate buffer (pH 7.3) containing 4% glutaraldehyde, and then post-fixed for 2 hours in osmium tetroxide ( $\text{OSO}_4$ ). After three times of washing in the same buffer, the worms were dehydrated using serial grades of escalating ethanol concentrations (10–100%) for ten minutes at a time, except for the final concentration (100%), two changes were used (30 min and 10 min, respectively). To finalize the dehydration, drying

process was started using the critical point drying in aqueous carbon dioxide. Finally, using an Edwards S150A sputter coater, worms were adhered to copper stubs using double-sided adhesive tape, then coated with gold powder, and studied under a scanning electron microscope (Model: JEOL, JXA-840A Electron Probe Micro analyzer).

### 2.4. Statistical Analysis

SPSS software version 22 was used to analyze the data. Non-parametric and post-hoc analysis was performed using Mann-Whitney and T-test, one-way analysis of variance (one-way ANOVA). P values less than 0.05 are considered to be significant [25].

## 3. Results and Discussion

### 3.1. LD<sub>50</sub> determination of scorpion and bee venoms

LD<sub>50</sub> of scorpion, *Leiurus quinquestriatus* venom, was calculated using serial concentrations of venom, from 0.1 mg/kg to 0.4 mg/kg, and mice were under observation for 24 h after venom injection. The data showed that nearly 50% of mice mortality was after administration of 0.1 mg/kg dose of venom, while 100% mortality was after 0.4 mg/kg dose (Figure 1). The LD<sub>50</sub> of bee, *Apis mellifera* venom (0.1mg/kg) was used as mentioned in the previous studies.

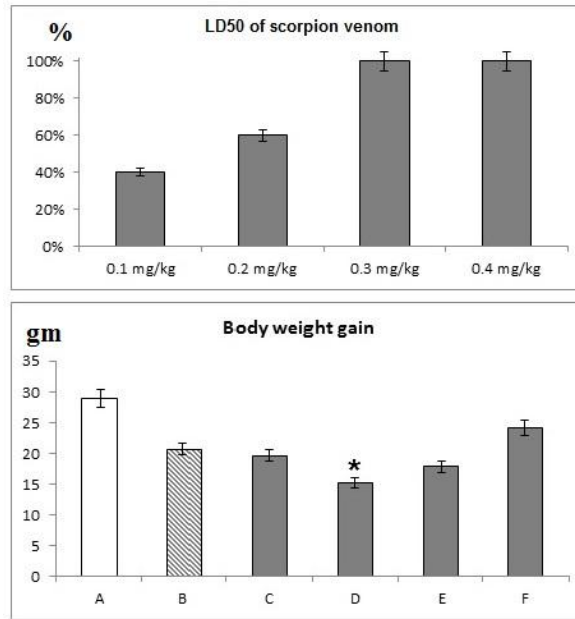
### 3.2. Body weight changes

The body weight of mice was measured before and after the experiment to evaluate the impact of venom on their health status using equation No. 1. The data showed a decrease in the body weight of infected mice ranged between 5 to 8 gm, while those treated with mixed venoms of scorpion and bee revealed a greater decrease in body weight reached to 15 g (Figure 1).

### 3.3. Measurement of liver function parameters

Liver function parameters, including Albumin level (Alb), Aminotransferases (ALT and AST), were measured in the serum of all mice groups. The data revealed significant changes ( $p < 0.01^{**}$ ) in liver function parameters of the infected non-treated group, where there was a decrease in (Alb) and an increase in (AST and ALT) ( $3.6 \pm 0.0$ ,  $2375 \pm 75$  and  $1700 \pm 400$ ) compared to the negative control group ( $6.2 \pm 0.5$ ,  $1047.3 \pm 31.1$  and  $125.8 \pm 8.8$ ). In treated groups (C, D, E, and F), the (Alb) level was slightly increased in group C ( $4.7 \pm 0.6$ ), while the other groups showed non-remarkable changes. Also, the mean (AST) level was significantly decreased ( $p < 0.01^{**}$  and  $< 0.05^*$ ) in groups F, C, and E, respectively (Table No. 1), while the mean (ALT) level was significantly decreased ( $< 0.01^{**}$ ) in group F only.

Research Article



**Figure 1.** Assessment of LD<sub>50</sub> of the Scorpion, *Leiurus quinquestriatus* venom showing the death percentage of male Swiss albino mice affected by different doses administered subcutaneously 24 hrs. Statistical analysis showing the administration effect of scorpion.

**Table 1.** Administration effect of Scorpion, *Leiurus quinquestriatus*, and bee, *Apis mellifera*, venoms on the liver function parameters and liver granuloma diameter of male Swiss albino (CD-1 strain) mice treated groups C, D, E, and F compared to the infected non-treated group B.

Groups Parameters	Group A	Group B	Group C	Group D	Group E	Group F
Alb (mg/dl)	6.2±0.5	3.6±0.0	4.7±0.6	3.4±0.6	3.3±0.4	3.2±0.4
	-----	-----	<b>0.21</b>	<b>0.52</b>	<b>0.62</b>	<b>0.41</b>
AST (U/L)	1047.3 ±31.1	2375±75	1365±13 5	2010±81 1	1733±50 3	1145±65
			<b>&lt;0.01**</b>	<b>0.23</b>	<b>&lt;0.05*</b>	<b>&lt;0.01**</b>
ALT (U/L)	125.8± 8.8	1700±40 0	1517±10 3	1900±76 9	1723±54 3	651±99
	-----	-----	<b>0.52</b>	<b>0.23</b>	<b>0.12</b>	<b>&lt;0.01**</b>
Granuloma diameter	-----	572±52	485±39	286±24	306±60	358±40
	-----	-----	<b>0.65</b>	<b>&lt;0.05*</b>	<b>&lt;0.05*</b>	<b>&lt;0.05*</b>

(\*,\*\* and \*\*\*p < 0.05, p < 0.01 and p < 0.001) (Alb) Albumin, (ALT) Alanine aminotransferase, (AST) Aspartate transaminase.

## Research Article

### 3.4. Measurement of kidney function parameters

Creatinine and urea levels were measured to evaluate the kidney function parameters during the infection and treatment of mice groups. The findings revealed a noticeable increase in the kidney function (urea and creatinine levels) of the infected non-treated group ( $42.5 \pm 0.5$  and  $0.7 \pm 0.0$ ) compared to the negative control group ( $31 \pm 1.3$  and  $0.4 \pm 0.1$ ). In treated groups (C, D, E, and F), the creatinine levels were decreased in all groups; however, it was decreased significantly ( $p < 0.05^*$ ) in group F ( $0.3 \pm 0.5$ ). Similarly, the urea levels were decreased in all groups, but decreased significantly ( $p < 0.05^*$ ) in group C ( $30.5 \pm 1.5$ ), Table 2.

**Table 2 . Administration effect of Scorpion, *Leiurus quinquestriatus*, and bee, *Apis mellifera* venoms on kidney function parameters of male Swiss albino mice (CD-1 strain) mice treated in groups C, D, E, and F compared to the infected non-treated group B.**

Groups Parameters	Group A	Group B	Group C	Group D	Group E	Group F
Creatinine (mg/dl)	$0.4 \pm 0.1$	$0.7 \pm 0.0$	$0.5 \pm 0.0$	$0.6 \pm 0.2$	$0.6 \pm 0.1$	$0.3 \pm 0.5$
	-----	-----	0.32	0.51	0.32	$< 0.05^*$
Urea (mg/dl)	$31 \pm 1.3$	$42.5 \pm 0.5$	$30.5 \pm 1.5$	$40 \pm 1.0$	$37 \pm 7.2$	$34.4 \pm 2.1$
	-----	-----	$< 0.05^*$	0.56	0.23	0.51

(\*,\*\* and \*\*\* $p \leq 0.05$ ,  $p \leq 0.01$  and  $p \leq 0.001$ ) (Creat) creatinine (Urea) Urea.

**Table 3 . Administration effect of Scorpion, *Leiurus quinquestriatus*, and bee, *Apis mellifera*, venoms on calcium and phosphorus serum profiles of the male Swiss albino (CD-1 strain) mice treated groups C, D, E, and F compared to the infected non-treated group B.**

Groups Parameters	Group A	Group B	Group C	Group D	Group E	Group F
Ca <sup>+</sup> (mg/dl)	$8.4 \pm 0.5$	$9 \pm 0.0$	$8.7 \pm 0.4$	$8.7 \pm 0.5$	$9 \pm 0.6$	$8.3 \pm 0.6$
	-----	-----	<b>0.52</b>	<b>0.34</b>	<b>0.32</b>	<b>0.52</b>
Ph <sup>+</sup> (mg/dl)	$6 \pm 0.6$	$6 \pm 0.4$	$6.3 \pm 0.3$	$6.3 \pm 0.9$	$6.1 \pm 0.6$	$6.4 \pm 0.8$
	-----	-----	<b>0.23</b>	<b>0.23</b>	<b>0.62</b>	<b>0.50</b>

(\*,\*\* and \*\*\* $p \leq 0.05$ ,  $p \leq 0.01$  and  $p \leq 0.001$ ) (Ph) Phosphorus, (Ca) Calcium.

### 3.5. Measurement of calcium and phosphorus serum profiles

Calcium and phosphorus levels of all treated groups showed no significant changes compared to the infected non-treated group Table 3.

### 3.6. Worm load count from the hepatic portal vein

As shown in (Figure 2), there was a significant decrease ( $p < 0.05^*$  and  $p < 0.01^{**}$ ) of male count in treated groups D, E, and F, and of male and coupled count in treated groups D and F, compared to group B.

## Research Article

### 3.7. Egg load of hepatic and intestinal tissues

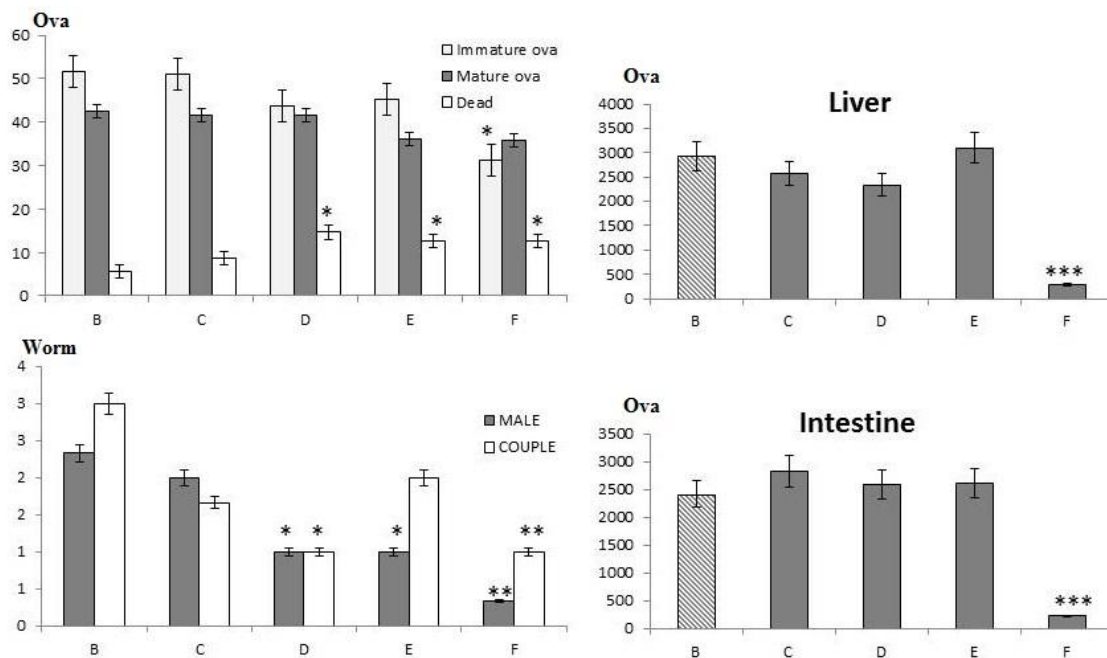
The data shown in (Figure 2) revealed a highly significant decrease ( $p<0.001***$ ) in the egg load of liver ( $284\pm12$ ) and intestinal ( $216\pm4$ ) tissues of the treated group F compared to group B.

### 3.8. Evaluate the impact of treatment on the oogram pattern

After the collection of ova from liver and intestinal tissues, they were examined to determine their status (immature, mature, and dead) and numbers. The findings revealed a significant decrease ( $p<0.05^*$ ) of immature eggs in the treated group F ( $31\pm3$ ) compared to the infected non-treated group ( $52\pm0.0$ ). On the contrary, the count of the dead eggs showed a significant increase ( $p<0.05^*$ ) in the treated groups D, E, and F ( $15\pm4$ ,  $13\pm1$ , and  $13\pm2$ ), respectively, compared to the infected non-treated ( $6\pm1$ ) (Figure 2).

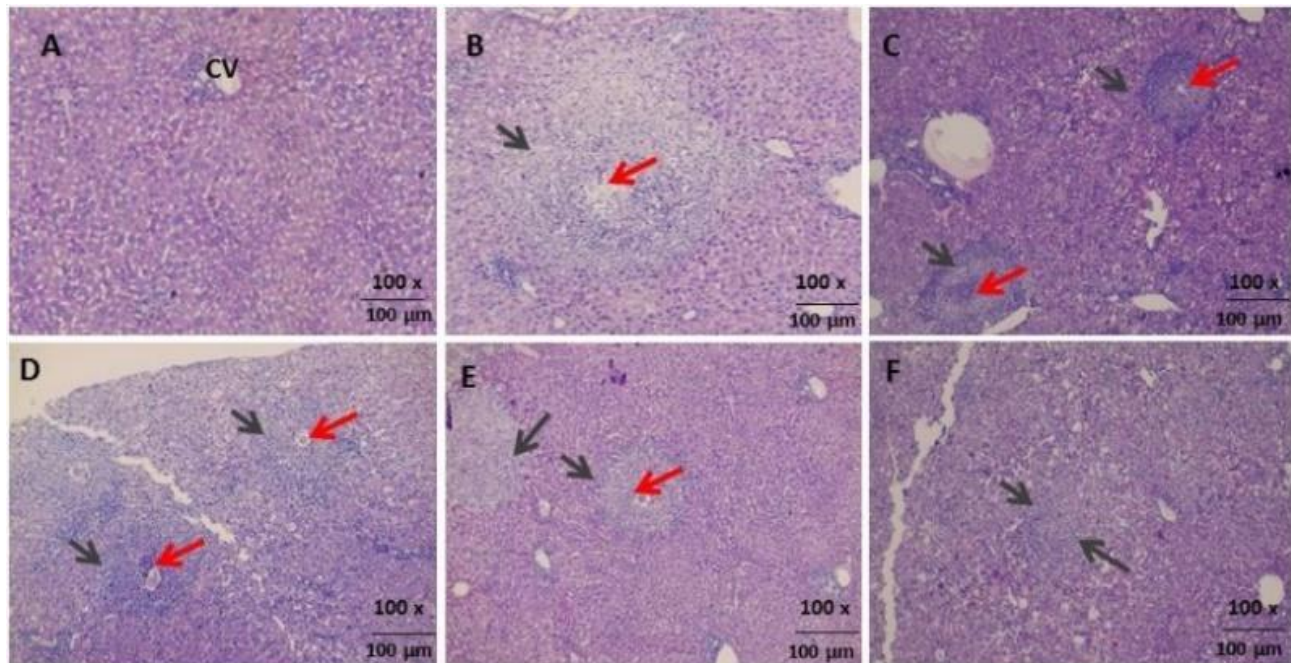
### 3.9. Histological observations of the liver and granuloma measurement

Liver sections were examined to clarify the histological changes upon the *Schistosoma mansoni* infection, granuloma formation, and treatment. While the negative control group showed a normal formation of liver cells with a clear central vein surrounded by cords of normal hepatocytes, the infected non-treated group showed a different shape of liver tissues, including granuloma formation around the *S. mansoni* eggs, which consist of leukocytic inflammatory cells, fibroblasts, and fibers. The figures showed enhancement in the formation of hepatic cells with mild degeneration in treated groups. The damage decrease in treated groups was reflected in egg numbers and the granuloma diameters as shown in Table 1. The F group showed the most enhancements of the treated groups, which appeared in increasing the percentage of mild fibrosis (fine fibrillary structure, and presence of binucleated cells) because of post-inflammatory repair compared to the infected non-treated group liver sections, (Figure 3).



**Figure 2.** Statistical analysis showing the administration effect of scorpion, *Leiurus quinquestriatus* and bee, *Apis mellifera* venoms on the number in the hepatic and intestine tissues and pattern of egg developmental stages in the intestinal tissues of male Swiss albino (CD-1 strain) mice treated groups C, D, E and F compared to infected group B. Statistical analysis showing the mean of the count of worms male (black) and couple (white) extracted from the hepatic portal vein of male Swiss albino (CD-1 strain) mice treated groups C, D, E, and F compared to the infected non-treated group B.

## Research Article



**Figure 3.** L.M photomicrograph of liver section showing: (A) normal hepatocytes and central vein (CV). (B) Infected non-treated sections showing *S. mansoni* eggs (Red arrow), with formed granuloma surrounded by lymphocytes and fibrocytic cells (black arrow) and (C, D, E, and F) infected-treated mice groups showing *S. mansoni* eggs (Red arrow) with formed granuloma (black arrow).

### 3.10. SEM observations of the worm's tegument

SEM Photomicrographs revealed some changes in the teguments of adult male worms recovered from the treated groups (C, D, E, &F) (see Figure 4 and 5) including sloughing and shorten of tegument spines, increasing the tegument ridges and grooves, changes in the tegument of gynaecophoric canal and appearance of protuberances and erosion and pores of tegument.

Developing a new treatment strategy based on natural extracts attracts attention nowadays against many diseases to get suitable, successful treatment with minimizing negative side effects. Clinical applications use multiple ways to find suitable and successful treatment against schistosomiasis, because praziquantel has lost its preference in treating schistosomiasis [26].

Naturally extracted venoms have a wide use as treatment of parasitic agents in many infections like Leishmania, Malaria, and Trypanosoma. To evaluate the scorpion, *Leiurus quinquestriatus*, and Bee, *Apis mellifera*, extracted venoms as antischistosomal, anti-inflammatory, and anti-fibrotic agents, this study was designed.


The treatment strategy of the current study started with the determination of scorpion venom lethal doses to get the suitable effective concentration with less loss and mortality rate ( $LD_{50}$ ). The results of the scorpion venom  $LD_{50}$  test revealed that 0.1mg/kg has a fatal effect on nearly 50 % of the total mice used. This finding is consistent with the data mentioned by [27], who determined the  $LD_{50}$  of scorpions, *Androctonus mauretanicus*, *Buthus occitanus*, and *viper*, *Cerastes cerastes* venoms in Swiss mice during their assessment of venoms activity in those animals. However, the bee, *Apis mellifera*, venom has been assessed by Mohamed et al (2016) [21]. They reported that the  $LD_{50}$  of *Apis mellifera* is 0.1mg/kg in Swiss albino mice.

The body weight changes were recorded during this study, and the results revealed that the schistosome infection causes body weight loss in the infected group, and this may be attributed to the feeding of adult worms on the host blood. This finding is in line with the report of [28], who mentioned the negative effects of schistosomiasis on nutritional parameters in humans, which include anemia and hemoglobin deficiency, physical fitness, and loss of appetite. However, the treated groups of mice with scorpion and bee venoms showed different responses in terms of body weight changes or improvement. While the treated group D showed a significant decrease in body weight compared to the

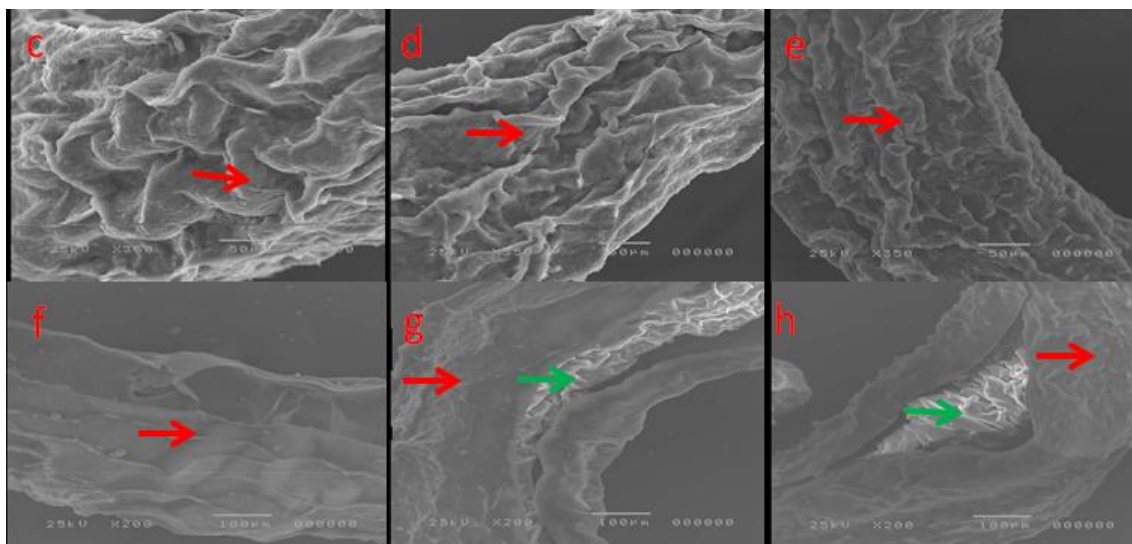
## Research Article

infected group, the decrease in body weight in the treated groups C and E was not significant. On the other hand, group F showed an improvement in body weight compared to the infected group, and this may be attributed to the significant decrease of worm parameters (worm count, hepatic and intestinal egg loads, immature and dead eggs, and granuloma diameter) in this group.

This finding is consistent with that of [29], who reported that bee venom increases the body weight and survivability of young pigs infected with immune diseases. It is also, in line with the results of [30], who mentioned that the scorpion, *Tityus serrulatus* venom, increases the body weight of the fetus in rats.



**Figure 4.** SEM Photomicrograph of *S. mansoni* teguments of adult male worms. Representative figures of adult male worms recovered from the positive control group, showing: Adult male tegument overview, a. Tubercles (white arrow), and b. tegmental spines (white arrow).



**Figure 5.** SEM Photomicrograph of *S. mansoni* teguments of adult male worms. Representative figures of adult male worms recovered from the treated groups (C, D, E, and F), showing: c. Sloughing and shortening of tegument spines (red arrow), d&e. Increasing the tegument ridges and grooves, g. Changes in the tegument of the gynaecophoric canal and appearance of protuberances (green arrow), h. Erosion and pores of the tegument.

Liver (ALT and AST) and kidney function parameters were significantly increased in the infected non-treated group compared to the negative control group; however, the albumin (Alb) level showed a significant decrease, and this may be attributed to the impact of worms' metabolites and presence of eggs in the tissues of many organs, particularly the liver. This result is in accordance with that of [31], who reported that the

liver injury indication markers, which include ALT, AST, ALP, and bilirubin, are associated with the reduced liver function and increased liver fibrosis and cirrhosis as a result of egg deposition in patients infected with *S. mansoni*. It is also consistent in part with the findings of [32], who mentioned that if AST and ALT levels are too high, it might be a sign of liver injury or short-term illness like cirrhosis. The treatment with scorpion and/or bee

## Research Article

venoms caused a significant decrease in (AST) in F, C, and E treated groups, while (ALT) is significantly decreased in the F treated group only compared to the infected non-treated group. The results also showed no significant changes in (Alb) levels in all treated groups compared to the infected non-treated group.

The significant amelioration of liver function may be attributed to the effect of some compounds found in bee and scorpion venoms, which contribute to liver tissue repair. This finding agrees with that of [33], who reported the role of bee venom as an anti-apoptotic compounds for hepatocytes upon ethanol-induced injury and in line with the result of [34], who reported the protective effect of bee venom on fibrosis-causing inflammatory diseases. Our result is also consistent with the findings of [35] who mentioned the role of scorpion venom in targeting K<sup>+</sup> channels and blocking the pathologic effects in autoimmune disorders, inflammatory injuries, and liver injury.

Similarly, the current study is in accordance with that of [36], which stated that, the scorpion's venom contains Butantoxin, which has a reversible action against K<sup>+</sup> channels, inhibition of T cells proliferation, and IL-2 production, which in turn is found to be suitable for decreasing the schistosomal fibrosis in the liver. The infected non-treated group of mice showed an increase in the level of kidney function parameters (creatinine and urea) compared to the negative control group, and this may be attributed to the effect of worms' metabolites and injuries caused by eggs on the tissues of many organs, particularly the kidney. This finding is in line with that of [37], who referred the increase of creatinine and urea to the injuries caused by schistosomal infection.

The treatment with scorpion and/or bee venoms caused a significant decrease ( $p < 0.05$ ) of Urea and Creatinine in the treated groups C and F, respectively, compared to the infected non-treated group. This improvement in kidney function upon the treatment with scorpion and/or bee venoms is due to the presence of some active ingredients in the venoms. These results are consistent with those of [38], who showed that the mice treated with BV enhanced the renal functions and reduced the renal tissue damage following cisplatin injection.

The current study revealed no significant changes were detected in the Calcium and phosphorus ion levels among the negative control, infected, and treated groups of mice, and this may be due to the calcium ions being affected by many factors other than the

infection with *Schistosoma*. This finding is consistent with that [39, 40]. [41] reported that the regulation of Ca<sup>+</sup> and Ph<sup>+</sup> levels in the blood depends primarily on three hormones: parathyroid, calcitonin, and 1,25-dihydroxy vitamin D. Ca<sup>+</sup> and Ph<sup>+</sup> homeostasis is controlled by the absorption in the gut, glomerular filtration, renal tubular reabsorption, and bone formation and reabsorption [42]. Some studies have reported the reducing effect of BV on the serum Ca<sup>+</sup> and Ph<sup>+</sup> levels after the entry into the bloodstream and the effect of melittin on decreasing Ca<sup>+</sup> levels of equine skeletal muscle [43].

The scorpion and/or bee venoms also, revealed significant changes in the worm parameters of treated groups compared to the infected non-treated group, where the findings showed a significant decrease in numbers of single males and coupled worms, a highly significant decrease of hepatic and intestinal egg load, and a significant decrease of granuloma diameter. This finding may be attributed to the impact of bioactive ingredients (free amino acids, phospholipase A2, melittin, apamin, histamine, and adrenaline) of scorpion and/or bee venoms, which mainly target the worm's tegument and make it more corrosive, and then cause death. This result is consistent with those of [44-46] who assessed the activity of bee venom on the number and viability of many parasites, like malaria, Tachyzoites of *Toxoplasma gondii*, and *Echinococcus granulosus*. Many studies are in line and support our results from these, one can mention the followings; [47] reported that phospholipase A2 enzymes, found in bee venom, may induce the release of arachidonic acid, PGE2 production in neutrophils treated with calcium ionophore, mast cells and mouse peritoneal macrophages which cause the paralysis of worms and increase its mortality. Quintero-Hernández et al (2013) reported that the administration of scorpion venom resulted in high permeability of membranes to sodium, blocking potassium channels and opening the voltage-sensitive sodium channels which causes calcium entry, relative hyperkalemia and hypernatremia, release of catecholamines and ultimately paralysis of worms [48], [11] mentioned that the scorpion venoms have antimicrobial peptides which significantly reduce the number of many parasites, including *Plasmodium*, *Entamoeba histolytica*, *Leishmania* and *Trypanosoma* in vitro studies.

Changes in the liver histopathological sections including granuloma between infected and treated groups illustrated that, the treated mice groups showed clear improvements in the

## Research Article

lobular arrangements and decreasing in the aggregates of inflammatory cells in both C, D, and F groups, also, group F showed presence of mild fibrosis of fibrillary structure, and presence of binucleated cells as a consequence of post-inflammatory repair, enhancement is clearly shown in the high treatment concentration [47].

The histopathological study revealed the presence of an increased size of granulomas and an abnormal structure of liver tissues compared to the negative control group. The treatment with scorpion and/or bee venoms indicated to an improvement and repair of liver tissue architecture represented by a significant decrease in granuloma diameter particularly in the treated groups D, E and F respectively. This finding is mostly attributed to the bioactive ingredients found in bee and scorpion venoms. This result also goes with that of [49], who mentioned that the bee venom can serve as an inflammatory modulator, affecting liver fibrosis by modulating the cytokines which promote inflammation of hepatocytes and liver damage in animal models. It is also in line with the study of [50-51] who reported that melittin (the main component of bee venom) has the potential to reduce the excessive immune responses and offer new options for the management of inflammatory illnesses. Moreover, melittin could be a viable substitute for preventing acute hepatic failure, and helps to restore hepatic cells to their normal status [51].

The tegument surface of adult worms, particularly that of males, has been studied to recognize the impact of scorpion and/or bee venoms on it. The observations obtained from SEM examination revealed some changes on the tegument surface, which can be summarized in sloughing and shortening of spines, increasing ridges and grooves, and erosion and pores. These changes were reported in some previous studies conducted on *Schistosoma* [20]. Finally, it is worth mentioning that, and upon the available information on web, the current study, if not the first, is one of the first studies which addresses the impact of venoms, particularly those of scorpion and bee venoms, on mice infected with schistosomiasis (in-vivo study).

## 4. Conclusion

The use of natural products, especially the animal venoms, is very important because some studies have shown promising results against many parasitic diseases, particularly schistosomiasis. The current study pronounced a significant

improvement in renal function as well as partial enhancement in liver function. The current study also revealed tangible results in some aspects of parasites, including a significant decrease in worms' load, hepatic and intestinal egg load, numbers of immature and dead eggs, granuloma diameter, and restored the normal liver tissue architecture. Finally, further studies are recommended on the crude and bioactive ingredients of scorpion and bee venoms

## Acknowledgement

The authors extend their appreciation to the Zoology Department members who spared no effort to complete this work.

## Conflict of interest

The authors claim no conflict of interest.

## Funding

This work was funded by a PhD thesis entitled "The potential effects of some animal venom on experimental mice infected with *Schistosoma mansoni*" by the corresponding author.

## Author contributions

O. A, N. A provided the research idea and revised the manuscript. I. A, running the experiment, analysis and interpretation of data, and writing the manuscript. A. E collection of venom samples, and analysis of the clinical data. M. M revising the manuscript.

## Ethics approval and consent to participate

This work has been done under a protocol approved by the Faculty of Science, Alazhar University, Assuit, Ethical Committee Review Board which confirmed that all experiments were performed in accordance with relevant guidelines and regulations of Alazhar University (No.AZHAR3/2024).

## Author information

**Corresponding author:** Ismail Atia\*

**E-mail:** [Dr.ismail\\_atia@yahoo.com](mailto:Dr.ismail_atia@yahoo.com)

**ORCID iD:** [0000-0001-6494-9619](https://orcid.org/0000-0001-6494-9619)

## References

- [1] Morsy, M. A., Gupta, S., Dora, C. P., Jhawar, V., Dhanawat, M., Mehta, D., Gupta, K., Nair, A., & El-Daly, M. (2023). Venoms classification and therapeutic

## Research Article

uses: a narrative review. *European Review for Medical & Pharmacological Sciences*, 27(4), 1633-1653. [https://doi.org/10.26355/eurrev\\_202302\\_31408](https://doi.org/10.26355/eurrev_202302_31408)

[2] Rave, L. J. G., Bravo, A. X. M., Castrillo, J. S., Marín, L.M. R., & Pereira, C. C. (2019). Scorpion venom: New promise in the treatment of cancer, *Acta biológica colombiana*, 24(2), 213-223. <https://doi.org/10.15446/abc.v24n2.71512>

[3] Nelwan, M. L. (2019). Schistosomiasis: life cycle, diagnosis, and control. *Current Therapeutic Research*, 91, 5-9. <https://doi.org/10.1016/j.curtheres.2019.06.001>

[4] World Health Organization, 2022. WHO guideline on control and elimination of human schistosomiasis.

[5] Al Amin, A. S. M., & Wadhwa, R. (2020). Helminthiasis. In *StatPearls*. StatPearls Publishing. <https://www.ncbi.nlm.nih.gov/books/NBK562330/>

[6] Acharya, S., Da'dara, A. A., & Skelly, P. J. (2021). Schistosome immunomodulators. *PLoS Pathogens*, 17(12), e1010064. <https://doi.org/10.1371/journal.ppat.1010064>

[7] Cupit, P. M., & Cunningham, C. (2015). What is the mechanism of action of praziquantel and how might resistance strike?. *Future medicinal chemistry*, 7(6), 701-705. <https://doi.org/104155/fmc.15.11>

[8] Aboagye, I. F., & Addison, Y. A. A. (2023). Praziquantel efficacy, urinary and intestinal schistosomiasis reinfection – a systematic review. *Pathogens and global health*, 117(7) 623-630. <https://doi.org/10.1080/20477724.2022.2145070>

[9] Ortiz, E., Gurrola, G.B., Schwartz, E.F., & Possani, L.D. (2015). Scorpion venom components as potential candidates for drug development. *Toxicon*, 93, 125-135. <https://doi.org/10.1016/j.toxicon.2014.11.233>

[10] Ahmadi, S., Knerr, J.M., Argemi, L., Bordon, K.C., Pucca, M.B., Cerni, F.A., Arantes, E.C., Çalışkan, F., & Laustsen, A.H. (2020). Scorpion venom: detriments and benefits. *Biomedicines*, 8 (5), 118, 1-31. <https://doi.org/10.3390/biomedicines8050118>

[11] Adade, C.M., & Souto-Padrón, T. (2015). Venoms as sources of novel anti-parasitic agents. *Toxins and Drug Discovery*, 1-31. [https://doi.org/10.1007/978-94-007-6726-3\\_4-1](https://doi.org/10.1007/978-94-007-6726-3_4-1)

[12] Wehbe, R., Frangieh, J., Rima, M., El Obeid, D., Sabatier, J. M., & Fajloun, Z. (2019). Bee venom: Overview of main compounds and bioactivities for

therapeutic interests. *Molecules* 24(16) 2997, 1-13. <https://doi.org/10.3390/molecules24162997>

[13] Hossen, M. S., Shapla, U. M., Gan, S. H., & Khalil, M. I. (2017). Impact of bee venom enzymes on diseases and immune responses. *Molecules*, 22(1), 25. <https://doi.org/10.3390/molecules22010025>

[14] Rady, I., Siddiqui, I. A., Rady, M., & Mukhtar, H. (2017). Melittin, a major peptide component of bee venom, and its conjugates in cancer therapy. *Cancer letters*, 402, 16-31. <https://doi.org/10.1016/j.canlet.2017.05.01>

[15] Kurek-Górecka, A., Komosinska-Vashev, K., Rzepecka-Stojko, A., & Olczyk, P. (2020). Bee venom in wound healing. *Molecules*, 26(1), 148. <https://doi.org/10.3390/molecules26010148>

[16] Khalil, A., Elesawy, B. H., Ali, T. M., & Ahmed, O.M. (2021). Bee venom: From venom to drug. *Molecules*, 26(16), 4941. <https://doi.org/10.3390/molecules26164941>

[17] El-Wahed, A. A. A., Khalifa, S. A., Elashal, M. H., Musharraf, S. G., Saeed, A., Khatib, A., ... & El-Seedi, H. R. (2021). Cosmetic applications of bee venom. *Toxins*, 13(11), 810. <https://doi.org/10.3390/toxins13110810>

[18] Tobassum, S., Tahir, H. M., Zahid, M. T., Gardner, Q. A., & Ahsan, M. M. (2018). Effect of milking method, diet, and temperature on venom production in scorpions. *Journal of Insect Science*, 18(4), 19. <https://doi.org/10.1093/jisesa/iey081>

[19] Van der Meijden, A., Koch, B., Van der Valk, T., Vargas-Muñoz, L. J., & Estrada-Gómez, S. (2017). Target-specificity in scorpions; comparing lethality of scorpion venoms across arthropods and vertebrates. *Toxins*, 9(10), 312. <https://doi.org/10.3390/toxins9100312>

[20] Mohamed, A. H., Hassab El-Nabi, S. E., Bayomi, A. E., & Abdelaal, A. A. (2016). Effect of bee venom or propolis on molecular and parasitological aspects of *Schistosoma mansoni* infected mice. *Journal of Parasitic Diseases*, 40(2), 390-400. <https://doi.org/10.1007/s12639-014-0516-5>

[21] Gurarie, D., King, C. H., Yoon, N., & Li, E. (2016). Refined stratified-worm-burden models that incorporate specific biological features of human and snail hosts provide better estimates of *Schistosoma* diagnosis, transmission, and control. *Parasites & Vectors*, 9(1), 1-19. <https://doi.org/10.1186/s13071-016-1681-4>

## Research Article

- [22] Schwartz, C., & Fallon, P. G. (2018). Schistosoma “eggsiting” the host: granuloma formation and egg excretion. *Frontiers in immunology*, 9, 2492. <https://doi.org/10.3389/fimmu.2018.02492>
- [23] Mati, V. L. T., & Melo, A. L. (2013). Current applications of oogram methodology in experimental schistosomiasis; fecundity of female Schistosoma mansoni and egg release in the intestine of AKR/J mice following immunomodulatory treatment with pentoxifylline. *Journal of Helminthology*, 87(1), 115-124. <https://doi.org/10.1017/S0022149X12000144>
- [24] Hasan, M. I., Das, S. K., & Chowdhury, E. H. A. (2021). A better and copacetic protocol for histopathological slide preparation using H&E stain: A review, *Journal of Fisheries*, 2, 57-67.
- [25] Siedlecki, S. L. (2020). Understanding descriptive research designs and methods. *Clinical Nurse Specialist*, 34(1), 8-12. <https://doi.org/10.1097/NUR.0000000000000493>
- [26] Cioli, D., Pica-Mattoccia, L., Basso, A., & Guidi, A. (2014). Schistosomiasis control: praziquantel forever?. *Molecular and biochemical parasitology*, 195(1), 23-29. <https://doi.org/10.1016/j.molbiopara.2014.06.002>
- [27] Daoudi, K., Chgoury, F., Rezzak, M., Bourouah, O., Boussadda, L., Soukri, A., Sabatier, J.-M., & Oukkache, N. (2017). Consequences of Androctonus mauretanicus and Buthus occitanus scorpion venoms on electrolyte levels in rabbits. *Heliyon*, 3(1), e00221. <https://doi.org/10.1016/j.heliyon.2016.e00221>
- [28] Stephenson, L. (1993). The impact of schistosomiasis on human nutrition. *Parasitology*, 107(S1) S107-S123. <https://doi.org/10.1017/S0031182000075545>
- [29] Han, Z.-G., Brindley, P.J., Wang, S.-Y., & Chen, Z. (2009). Schistosoma genomics: new perspectives on schistosome biology and host-parasite interaction. *Annual review of genomics and human genetics*, 10, 211-240. <https://doi.org/10.1146/annurev-genom-082908-150036>
- [30] Skelly, P.J., Da'dara, A.A., Li, X.-H., Castro-Borges, W., & Wilson, R.A. (2014). Schistosome feeding and regurgitation. *PLoS Pathogens*, 10(8), e1004246. <https://doi.org/10.1371/journal.ppat.1004246>
- [31] Leite, L.A.C., Pimenta Filho, A.A., Fonseca, C.S.M.de, Santos, B.S.de, Ferreira, R.de C.da S., Montenegro, S.M.L., .....& Lima, V.L.de M. (2013). Hemostatic dysfunction is increased in patients with hepatosplenic schistosomiasis mansoni and advanced periportal fibrosis, *PLoS Neglected Tropical Diseases*, 7(7), e2314. <https://doi.org/10.1371/journal.pntd.0002314>
- [32] McGill, M.R. (2016). The past and present of serum aminotransferases and the future of liver injury biomarkers. *EXCLI journal*, 15, 817. <https://doi.org/10.17179/excli2016-800>
- [33] Chhimwal, J., Sharma, S., Kulurkar, P., & Patial, V. (2020). Crocin attenuates CCl<sub>4</sub>-induced liver fibrosis via PPAR-γ mediated modulation of inflammation and fibrogenesis in rats. *Human & Experimental Toxicology*, 39(12), 1639-1649. <https://doi.org/10.1177/0960327120937048>
- [34] Abo-Zaid, M.A., Yatimi, K.A., & Ismail, A.H. (2023). The role of bee venom on immunological and hematological parameters in albino rats. *Egyptian Journal of Immunology*, 30(2), 11-25. <https://doi.org/10.55133/eji.300202>
- [35] Petricevich, V.L. (2010). Scorpion venom and the inflammatory response. *Mediators of inflammation*, 2010, 903295. <https://doi.org/10.1155/2010/903295>
- [36] Oliveira-Mendes, B.B.R.de, Miranda, S.E.M., Sales-Medina, D.F., Magalhaes, B.de F., Kalapothakis, Y., Souza, R.P.d., Cardoso, V.N., de Barros, A.L.B., Guerra-Duarte, C., & Kalapothakis, E. (2019). Inhibition of Tityus serrulatus venom hyaluronidase affects venom biodistribution. *PLoS Neglected Tropical Diseases*, 13(4), e0007048. <https://doi.org/10.1371/journal.pntd.0007048>
- [37] Duarte, D.B., De Francesco Daher, E., Pinheiro, M.E., & Oliveira, M.J.C. (2020). Schistosomiasis mansoni-associated kidney disease, *Tropical Nephrology* 113-129. [https://doi.org/10.1007/978-3-030-44500-3\\_9](https://doi.org/10.1007/978-3-030-44500-3_9)
- [38] Kim, H., Lee, G., Park, S., Chung, H.-S., Lee, H., Kim, J.-Y., ...& Bae, H. (2013). Bee venom mitigates cisplatin-induced nephrotoxicity by regulating CD4<sup>+</sup> CD25<sup>+</sup> Foxp3<sup>+</sup> regulatory T Cells in mice. *Evidence-Based Complementary and Alternative Medicine*, 2013(1), 879845. <https://doi.org/10.1155/2013/879845>
- [39] Mostafa, O. M. S., (2007). Effects of *Schistosoma mansoni* and *Schistosoma haematobium* infections on calcium content in their intermediate hosts. *Parasitology research*, 101, 963-966. <https://doi.org/10.1007/s00436-007-0566-z>
- [40] Tunholi-Alves, V. M., Tunholi, V. M., Garcia, J. S., Costa-Neto, S. F., Maldonado, A., Santos, M., Thiengo, S. C., &

## Research Article

- Pinheiro, J., (2014). Changes in the calcium metabolism of *Biomphalaria glabrata* experimentally infected with *Angiostrongylus cantonensis*. *Journal of helminthology*, 88(2), 160-165. <https://doi.org/10.1017/S0022149X12000867>
- [41] Mundy, G. R., & Guise, T. A. (1999). Hormonal control of calcium homeostasis. *Clinical chemistry*, 45(8), 1347-1352. <https://doi.org/10.1093/clinchem/45.8.1347>
- [42] Li, X., Zhang, D., & Bryden, W. (2017). Calcium and phosphorus metabolism and nutrition of poultry: are current diets formulated in excess?. *Animal Production Science*, 57(11), 2304-2310. <https://doi.org/10.1071/AN17389>
- [43] Kang, H.-S., Kim, S.-J., Lee, M.-Y., Jeon, S.-H., Kim, S.-Z., & Kim, J.-S. (2008). The cardiovascular depression caused by bee venom in Sprague–Dawley rats associated with a decrease of developed pressure in the left ventricular and the ratio of ionized calcium/ionized magnesium, *The American journal of Chinese Medicine*, 36(03), 505-516. <https://doi.org/10.1142/S0192415X08005941>
- [44] Al-Malki, E.S., & Abdelsater, N. (2020). In vitro scolical effects of *Androctonus crassicauda* (Olivier, 1807) venom against the protoscolices of *Echinococcus granulosus*. *Saudi Journal of Biological Sciences*, 27(7), 1760-1765. <https://doi.org/10.1016/j.sjbs.2020.05.014>
- [45] Tonk, M., Vilcinskas, A., Grevelding, C.G., & Haerberlein, S. (2020). Anthelmintic activity of assassin bug venom against the blood fluke *Schistosoma mansoni*. *Antibiotics*, 9(10), 664. <https://doi.org/10.3390/antibiotics9100664>
- [46] Rostamkolaie, L. K., Hamidinejat, H., Jalali, M. H. R., Varzi, H. N., Abadshapouri, M. R. S., & Jafari, H. (2022). Inhibitory effect of *Hemiscorpius lepturus* Scorpion Venom Fractions on Tachyzoites of *Toxoplasma gondii*. *Iranian Journal of Parasitology*, 17(1), 79.
- [47] Peng, Z., Chang, Y., Fan, J., Ji, W., & Su, C. (2021). Phospholipase A2 superfamily in cancer. *Cancer Letters*, 497, 165-177. <https://doi.org/10.1016/j.canlet.2020.10.021>
- [48] Quintero-Hernández, V., Jiménez-Vargas, J., Gurrola, G., Valdivia, H., & Possani, L., (2013). Scorpion venom components that affect ion-channels function. *Toxicon*, 76, 328-342. <https://doi.org/10.1016/j.toxicon.2013.07.012>
- [49] Lee, W.-R., Pak, S.C., & Park, K.-K., (2015). The protective effect of bee venom on fibrosis causing inflammatory diseases. *Toxins*, 7(11), 4758-4772. <https://doi.org/10.3390/toxins7114758>
- [50] Lee, G., & Bae, H., (2016). Anti-inflammatory applications of melittin, a major component of bee venom: detailed mechanism of action and adverse effects. *Molecules*, 21(5), 616. <https://doi.org/10.3390/molecules21050616>
- [51] Berumen, J., Baglieri, J., Kisseleva, T., & Mekeel, K., (2021). Liver fibrosis: Pathophysiology and clinical implications. *WIREs Mechanisms of Disease*, 13(1), e1499. <https://doi.org/10.1002/wsbm.1499>